

# Casebook

Volume 28 | Issue 1 | **May 2020**

Asia



## A tale of greed and dishonesty

How we reversed the demands of an excessive negligence claim

Page 15

### From the case files

#### Surgical emphysema in the neck leads to a claim

We support anaesthetist Dr E over a rare development during a shoulder arthroscopy

#### Nitrofurantoin complication goes to trial

GP Dr X receives a claim after a patient develops breathlessness linked to nitrofurantoin

#### Words: A view from the other side

Find out how even the most everyday forms of communication can have an unintended impact

## Every issue



### Welcome

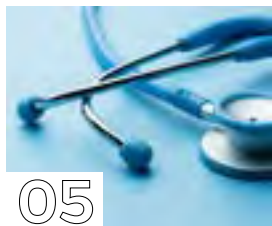Dr Rob Hendry, Editor-in-Chief of *Casebook*, welcomes you to this edition and looks at the global issue of burnout.



### Over to you

What did you think about the last issue of *Casebook*? All comments and suggestions welcome.

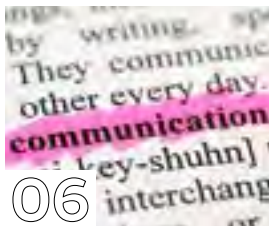
## Articles



05

### Reflections on clinical practice from a medicolegal consultant

Dr Zoe Neill, former GP and new Medicolegal Consultant at Medical Protection, reflects on her first few weeks in the job and what she wishes she'd known when in practice.



06

### Words: A view from the other side

Dr Emma Green, Medicolegal Consultant at Medical Protection, looks at how even the most everyday forms of communication can have an unintended impact.



16

### Scaphoid injuries: pitfalls and pearls

The failure to diagnose scaphoid injuries is a common source of claims at Medical Protection. Dr Emma Green, Medicolegal Consultant at Medical Protection and Emergency Medicine Doctor, advises on the common pitfalls and how to avoid them.

Opinions expressed herein are those of the authors. Pictures should not be relied upon as accurate representations of clinical situations. © The Medical Protection Society Limited 2020. All rights are reserved.

ISSN 1366 4409

*Casebook* is designed and produced twice a year by Medical Protection. Regional editions of each issue are mailed to all Medical Protection members worldwide.

The Medical Protection Society Limited ("MPS") is a company limited by guarantee registered in England with company number 00036142 at Level 19, The Shard, 32 London Bridge Street, London, SE1 9SG.

MPS is not an insurance company. All the benefits of membership of MPS are discretionary as set out in the Memorandum and Articles of Association. MPS® and Medical Protection® are registered trademarks.

Cover: @MicroStockHub@gettyimages.co.uk

*Casebook* publishes medicolegal reports as an educational aid to Medical Protection members and to act as a risk management tool. The reports are based on issues arising in Medical Protection cases from around the world. Facts have been altered to preserve confidentiality.

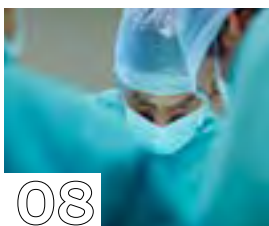## Case reports



07

### A risk of harm


A psychiatric patient at risk of suicide is left unsupervised and self-harms, leading to a claim against the consultant psychiatrist. What happened next and how did Medical Protection provide support?



08

### Surgical emphysema in the neck leads to a claim

Anaesthetist Dr E receives a claim following a shoulder arthroscopy – how did Medical Protection assist?



09

### An expensive lack of consent?


Consultant ophthalmologist Dr B receives a claim after a problematic laser eye procedure – what part did the consent process play in the final outcome?



12

### Nitrofurantoin complication goes to trial

When a patient on nitrofurantoin develops breathing difficulties, a claim is made against the GPs involved. Find out what happened when Medical Protection defended the claim to trial.



15

### A tale of greed and dishonesty

Patient Mr F makes a high cost negligence claim against GP Dr A, but Medical Protection uncovers inconsistencies in his allegations. How did the legal team resolve the case?

Get the most from your membership...



Visit our website for publications, news, events and other information: [medicalprotection.org](https://www.medicalprotection.org)



Follow our tweets at: @MPS\_medical



medical protection

## Editorial and production



Dr Rob **Hendry**  
Editor-in-chief



Gareth **Gillespie**  
Editor

## Contributors



Marshal **Ahluwalia**



Dr Clare **Devlin**



Dr Emma **Green**



Dr Dawn **McGuire**



Dr Heidi **Mounsey**



Dr Zoe **Neill**



Dr Clare **Redmond**



Suzanne **Tate**

### Production

**Emma Senior** Production and Lead Designer

**Conor Walsh** Designer

**Print** Sampoorna

**Please address all correspondence to:**

Casebook Editor, Medical Protection, Victoria House, 2 Victoria Place, Leeds LS11 5AE, United Kingdom

**casebook@medicalprotection.org**

## Welcome

Dr Rob **Hendry**  
Editor-in-chief



**I**n what is my first edition as the editor-in-chief of *Casebook*, may I first express how delighted I am to be overseeing such a long-standing publication that I know is highly valued by Medical Protection members worldwide. My predecessor Dr Marika Davies did a fantastic job and it's a real honour to be in the hotseat.

Having been Medical Director at Medical Protection for a number of years, I have been fortunate enough to meet many members around the world in person, and directly hear your views on the many issues affecting the profession. One such issue that has had a great deal of recent coverage – despite it hardly being new – is burnout, and this is something that Medical Protection on the whole has been campaigning about around the world, raising awareness of the problem across both medicine and dentistry and its potential impact on clinician wellbeing and patient safety.

I know from speaking to many of you how popular *Casebook* is, particularly the case reports. As doctors we tend to learn from listening to patients and their stories. So when things go wrong, or are alleged to go wrong, in medicine, we can learn a lot about avoiding problems by hearing about the experience of our colleagues and fellow Medical Protection members. Many cases also illustrate the fierce commitment applied by our teams behind the scenes to fight your corner and protect your reputations.

As part of this commitment to providing you with the best possible service, we have recently confirmed plans to base our Irish and South African case and claims handling functions in-country, with new offices opening in Ireland and South Africa during the next 12-18 months. This means we will be able to supply even more tailored support in dealing with issues of local relevance and urgency, which can range from handling complaints, writing reports and general medicolegal advice to more complex issues such as claims of clinical negligence, regulatory matters, inquests and criminal investigations.

I hope you enjoy my first edition of *Casebook* and please do share your views on the publication or any other issue with me via

**casebook@medicalprotection.org**

**Dr Rob Hendry**

Medical Director, Medical Protection and Editor-in-chief, *Casebook*

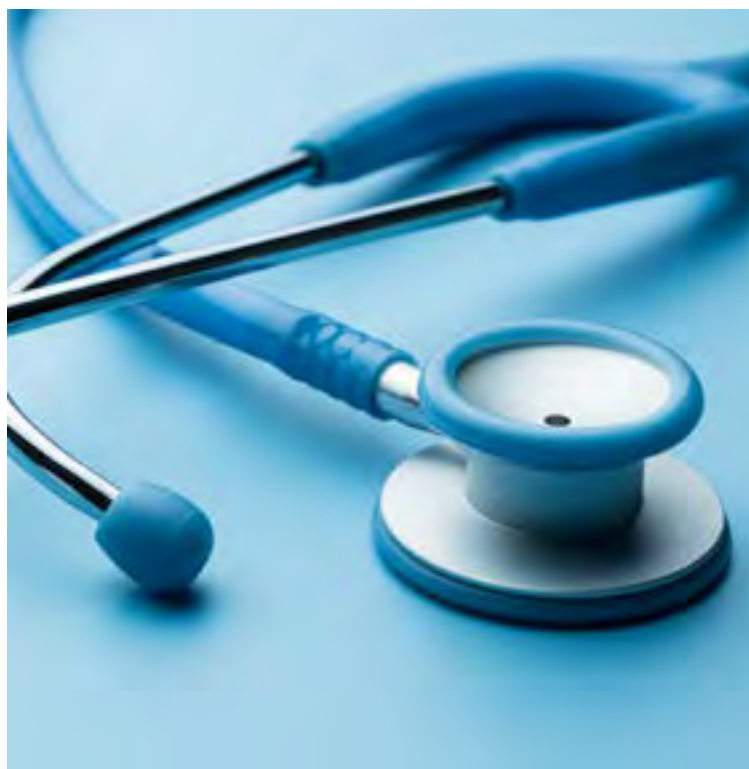

When you have finished with this magazine please recycle it.

# Reflections on clinical practice from a medicolegal consultant



*Dr Zoe Neill, former GP and new Medicolegal Consultant at Medical Protection, reflects on her first few weeks in the job and what she wishes she'd known when in practice*



**A**s a former GP principal and locum GP, I thought I was fully informed about all the medicolegal aspects of my practice. Medical Protection had supported me through a few patient complaints in the past, and some other tricky work issues. And while I knew I would eventually be at the mercy of statistics and face litigation at some point in my career, I'd always felt reassured that Medical Protection would be there for me.

Now having started working for Medical Protection, it was after just a few days in my new role as a medicolegal consultant that I realised how the support of Medical Protection is very much built on a reciprocal relationship, and I don't mean just financially. Members have got responsibilities too.

## Subscription renewals and the growing to-do list

I am sure I'm not alone in procrastinating about life admin tasks, which my pile of opened 'to do' mail in my kitchen demonstrates. However, any letter starting with "renewal of your policy" should, but doesn't, get immediate attention, despite us knowing we should – as Mark Twain once said – "eat the frog" first.

The reality is quite different. I have quickly realised that an inaccurate description of my current work pattern (job title, grade, sessions worked, type of work undertaken) or a bounced direct debit payment could, perhaps, lead to Medical Protection not being there when I need them.

**Top tip #1: Keep Medical Protection abreast of any of these changes, as soon as they happen.**

## Medical Council referrals – help us to help you

Complaints and litigation now pale into insignificance compared to the anecdotes I've already heard about Medical Council referrals, and how having Medical Protection on side is invaluable. The ostrich approach is not recommended – please let Medical Protection have a bit more notice than an hour before your Medical Council hearing!

It has been heartening to see how Medical Protection truly understands the catastrophic impact Medical Council proceedings can have on a doctor, both personally and professionally. I have already lost count of the times I've put my head in my hands in disbelief, but also in recognition of how 'Swiss cheese' holes in systems can land any of us in trouble.

**Top tip #2: If you are asked to see a patient in passing – in a corridor, car park, the hospital shop – or "just as a favour", you must treat it with just as much caution as a full clinic consultation. Even if you help someone in the street, go home and make a note of it as soon as you can. If you give any advice to your aunt, hairdresser or whoever, then please make sure it's the safest and most clinically cautious advice possible.**

## Increasingly high standards for doctors

I am under no illusion that gold standard clinical practice is virtually impossible in the frenetic world of healthcare, where corridor medicine is now an Emergency Department staple. The fact that the Medical Council holds doctors to what are – over a 35-to 40-year career – extremely high standards of personal and professional conduct, means that being a doctor is a profession not to be entered into lightly, but reverently, discreetly, advisedly and soberly.

**Top tip #3: "The reputation of the profession is more important than the fortunes of any individual member. Membership of a profession brings many benefits, but that is part of the price."** (Bolton v Law Society [1994] WLR 512)

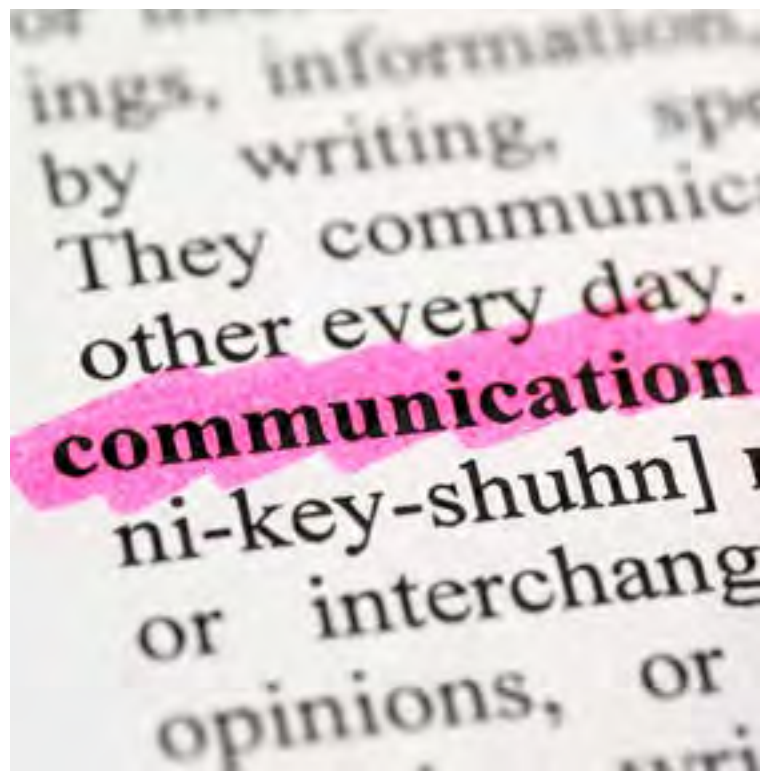At times it feels like doctors are expected to be superhuman in their professional and personal lives. Since erring is part of being human, it is no wonder that Medical Protection phone lines are constantly buzzing, and no wonder that all doctors fear that letter from the Medical Council. In many ways, it is surprising that so many of us don't ever get that letter.



# Words: A view from the other side



Dr Emma **Green**, *Medicolegal Consultant at Medical Protection*, looks at how even the most everyday forms of communication can have an unintended impact



*“Words are, of course, the most powerful drug used by mankind.”*

*Rudyard Kipling*

**A**s medical professionals our words can be so powerful: they can change lives, for better and worse. But they can be interpreted in so many different ways. They can make us and they can break us.

Since moving from clinical work to my role as a medicolegal consultant, I have been more aware of the impact that words can have on us as professionals and the impact words can have on our colleagues. On my decision to leave clinical practice, I have frequently heard the words “but you took the easy route” or “it’s alright for you as you don’t do this anymore” and on many occasions these words come from a place of hurt and anger.

They come from a member under stress because they have received a letter of clinical negligence. A member under stress because they care about their patient, but something has gone wrong. A member under stress because there is no merit to the claim but they still have to go through the processes.

I do not always see these people as members, but colleagues. Colleagues whose shoes I have walked in. Colleagues with whom I truly empathise. Yet these words can affect the early relationship and the support that, ultimately, I am here to offer.

## Communication and claims

Words themselves often form the basis of claims, from a throwaway comment in front of a patient to a more poignant act of belittling a colleague who has missed a blood test or delayed a diagnosis because the wrong route of investigation was taken. We have a duty of candour to ensure patients are aware when errors have occurred. But how we tell them and the words we use can lead to them seeking legal advice and initiating the claims process, when this was not previously a considered option. Research has shown that claims initiated after adverse outcomes are not always associated with error – and effective communication can reduce claims.<sup>1</sup>

Written communication of errors can sometimes result in patients being copied into letters where the mistakes are bluntly pointed out using accusatory terminology. Some examples being “this test was clearly missed” or “this result was wrongly filed”. Whilst the professional duty to point out mistakes can enable important learning for colleagues, the terminology we use can perpetuate a culture of blame and shifting of responsibility without always knowing the facts.

I know I have been guilty as a junior doctor of sometimes being so proud that I had spotted a diagnosis that someone else had missed or wondering why a patient had been sent to the emergency department unnecessarily, that I also probably used my words in a way that was ultimately not very supportive. As I enter back into clinical shifts, I now reflect on whether any of those encounters became claims, and I know that my future practice will be different, having seen the effect our words can have from a medicolegal perspective.

Of course, patients should be entitled to compensation when an error has occurred that caused harm. But I have often wondered how many of the claims I see would be reduced if we all took a moment to consider how we tell patients about errors and if we remember our colleagues are human too and how this may impact them.

The take-home message? You won’t save lives from this article but it is nice to be nice, so please “Don’t gobblefunk around with words” (Roald Dahl – *BFG*) and remember: “Even the smallest of words can be the ones to hurt you, or save you” (Natsuki Takaya).

## Conclusion

*The way you communicate with a patient when something has gone wrong is one of the key factors in determining if a patient will make a complaint or a claim. However, most doctors receive little or no formal training in how to communicate when involved in these difficult and stressful situations.*

*Medical Protection’s Risk Prevention team runs the workshop Mastering Adverse Outcomes, which provides you with powerful techniques that can reduce your exposure to the risk of complaints or claims. Visit [medicalprotection.org](http://medicalprotection.org) to find out more and book your place.*

## References

1. Localio 1991, Studdert D et al 2000, Davis et al 2002, Bismark et al 2006

# A risk of harm



By Dr Clare **Redmond**, *Medicolegal Consultant, Medical Protection*



**M**iss A, a 30-year-old teacher, saw Dr W, a consultant psychiatrist, in the outpatient clinic. Dr W noted Miss A's diagnosis of bipolar affective disorder, her previous hospital admission for depression and her history of a significant overdose of antidepressant medication. Dr W found Miss A to be severely depressed with psychotic symptoms. Miss A reported thoughts of taking a further overdose and Dr W arranged her admission informally to hospital.

During Miss A's admission Dr W stopped her antidepressant medication, allowing a wash-out period before commencing a new antidepressant and titrating up the dose. He increased Miss A's antipsychotic medication and recommended she be placed on close observations due to continued expression of suicidal ideation. He documented that Miss A appeared guarded and perplexed, did not interact with staff or other patients on the ward, and spent long periods in her nightwear, lying on her bed. He did not document the content of her suicidal thoughts. Dr W reiterated to nursing staff that close observations should continue.

During the third week of her admission, Miss A asked to go home. Miss A's named nurse left Miss A alone to contact the team doctor to ask whether Miss A required assessment. While alone in her room, Miss A set fire to her night clothes with a cigarette lighter and sustained burns to her neck, chest and abdomen. She was transferred to the Emergency Department and then to the plastic surgical team and remained an inpatient on the burns unit for three months, requiring skin grafts to 20% of her body.

Miss A made a good recovery from this incident and subsequently brought a claim against Dr W and the hospital. She alleged

Dr W had failed to prescribe adequate doses of medication to ensure the optimal level of improvement in her mental health symptoms, failed to adequately assess the level of risk she posed, and failed to ensure constant specialist nursing care was provided to supervise her adequately during her hospital stay. She also alleged the hospital had failed to ensure she did not have access to a cigarette lighter. Miss A claimed that she would not have suffered the severe burns and subsequent post-traumatic stress disorder if not for these failings.

## Expert opinion

An expert opinion was sought from a psychiatrist. The expert made no criticism of the medication regime and changes but was critical of the communication between Dr W and nursing staff over the meaning of the words "close observation", and the lack of a policy setting this out. She was also of the view that additional nursing staff should have been requested to ensure one-to-one nursing of the patient during her admission. She was critical of the hospital for allowing the patient access to a lighter on the ward, and concluded that the incident could have been avoided if these failures had not occurred.

Dr W acknowledged Miss A had been the most unwell patient on the ward at the time and in hindsight agreed that additional nursing staff should have been requested. Dr W highlighted that there was pressure on consultants not to request additional nursing staff due to cost implications. He also acknowledged that by close observations he had expected the patient to be within sight of a member of nursing staff at all times but had not ever communicated this specifically to the ward staff.

The claim was settled for a substantial sum, with the hospital contributing to the settlement.

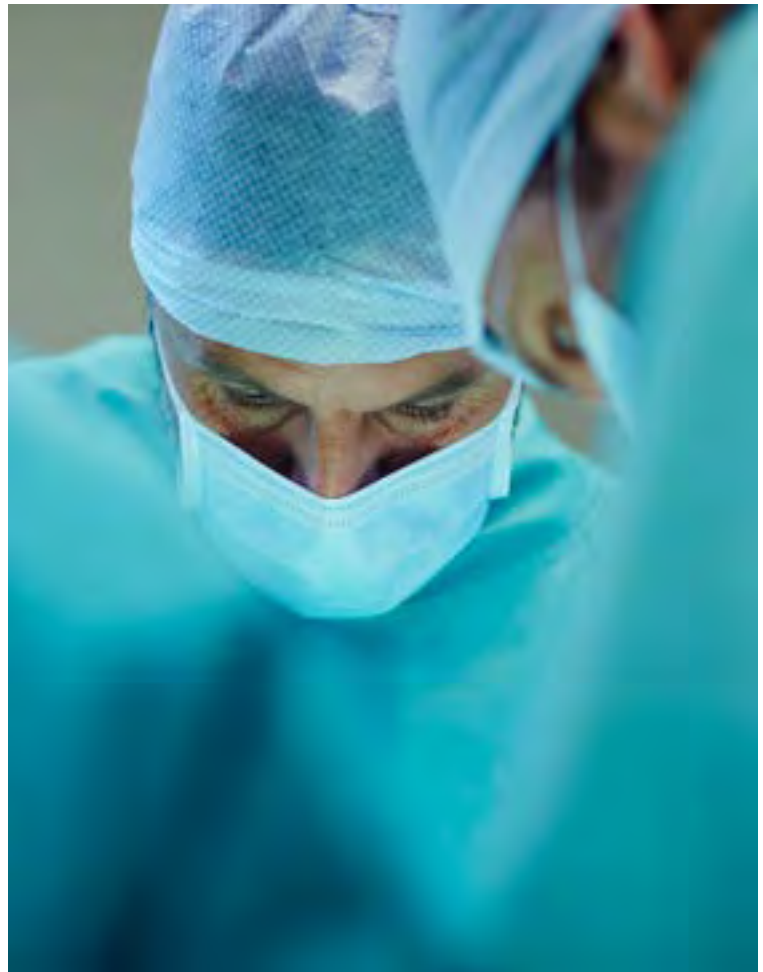
## Learning points

- **Mental health units should have clear policies regarding observation levels and all staff should be aware of these. The observation level deemed appropriate for each patient should be clearly discussed with ward staff and documented within the notes, both on admission and whenever changes are made. The justification for any changes in the level of observation should be clearly documented.**
- **Robust risk assessment is always important. Risk assessment tools are available, and you should be familiar with any relevant local policies regarding these. Decisions made about the risk posed by a patient to themselves or others should be clearly documented and communicated.**
- **Mental health units should also have policies surrounding the requirement to check patient's belongings when they are admitted and for removing any items that may pose a risk, including lighters and any sharp implements.**
- **If a lack of resources results in patient safety concerns, these should be raised by the clinician involved.**

### Further reading

Royal College of Psychiatrists; *Self-harm, suicide and risk: a summary* (2010) [rcpsych.ac.uk/pdf/ps03-2010x.pdf](https://www.rcpsych.ac.uk/pdf/ps03-2010x.pdf)

# Surgical emphysema in the neck leads to a claim



By Suzanne **Tate**, Litigation Solicitor, and Dr Clare **Devlin**, Medicolegal Consultant, Medical Protection

**M**s R underwent a shoulder arthroscopy under general anaesthetic and consultant anaesthetist Dr E also administered an interscalene block prior to the surgery for pain relief. Postoperatively she developed a sore throat and hoarseness, and produced some blood-stained sputum, so she was kept in overnight. After discharge the following day, she contacted the hospital complaining of a sore throat, difficulty swallowing and otalgia. On readmission, haemoptysis was recorded, together with a hoarse voice and bilateral neck crepitus. She was kept under close observation to ensure her airway was not compromised by the surgical emphysema, which later spread to her face and chest wall.

Over the months that followed she experienced alterations in her voice, which was rough, strained and breathy, and caused difficulty in her recreational singing in a choir. An ENT voice clinic diagnosed muscle tension dysphonia, a functional disorder of the laryngeal muscles, for which she underwent speech therapy, with partial improvement. She also complained of ongoing neck pain.

## The claim

Ms R made a claim against Dr E for the discomfort she suffered.

Consultant anaesthetist and ENT experts tried to unpick the aetiology of this rare and unexpected complication. Ms R alleged a gross error in needling when Dr E administered the interscalene block,

puncturing her trachea and causing the surgical emphysema. This explanation was never accepted by our experts.

Firstly, such a complication has never been reported for an interscalene block. Secondly, there were a number of logical arguments why this was highly unlikely to have been the explanation. The length of the needle used by Dr E meant it was unlikely the tip of the needle would have reached Ms R's trachea from its entry point – certainly not without inserting the needle right up to its hub and probably applying further pressure.

For the needle to reach the trachea from its point of entry, it is likely to have passed through the carotid artery and surrounding structures, which would have caused immediate and significant complications, which did not occur during Ms R's surgery. Also, the tip of the needle used was so fine that a simple puncture was unlikely to have been sufficient to allow air to escape. The trachea is sometimes punctured with a needle for other therapeutic reasons and this does not lead to surgical emphysema. Our ENT expert thought the tip of the needle would have had to have been used to scrape the trachea in a knife-like motion in order to cause a laceration sufficient to allow air to escape.

Experts on both sides had ruled out a pneumothorax, or air escaping from insufflation of the surgical site in the shoulder, as possible causes.

The remaining and most likely explanation was a rupture of the trachea during intubation. Whilst rare, this is a recognised and usually non-negligent complication of intubation. This explanation was not accepted by Ms R's experts, but if this explanation had been preferred by a court Ms R would have asserted this was also negligent. There, was, however, no evidence of any negligence on Dr E's part during the intubation period.

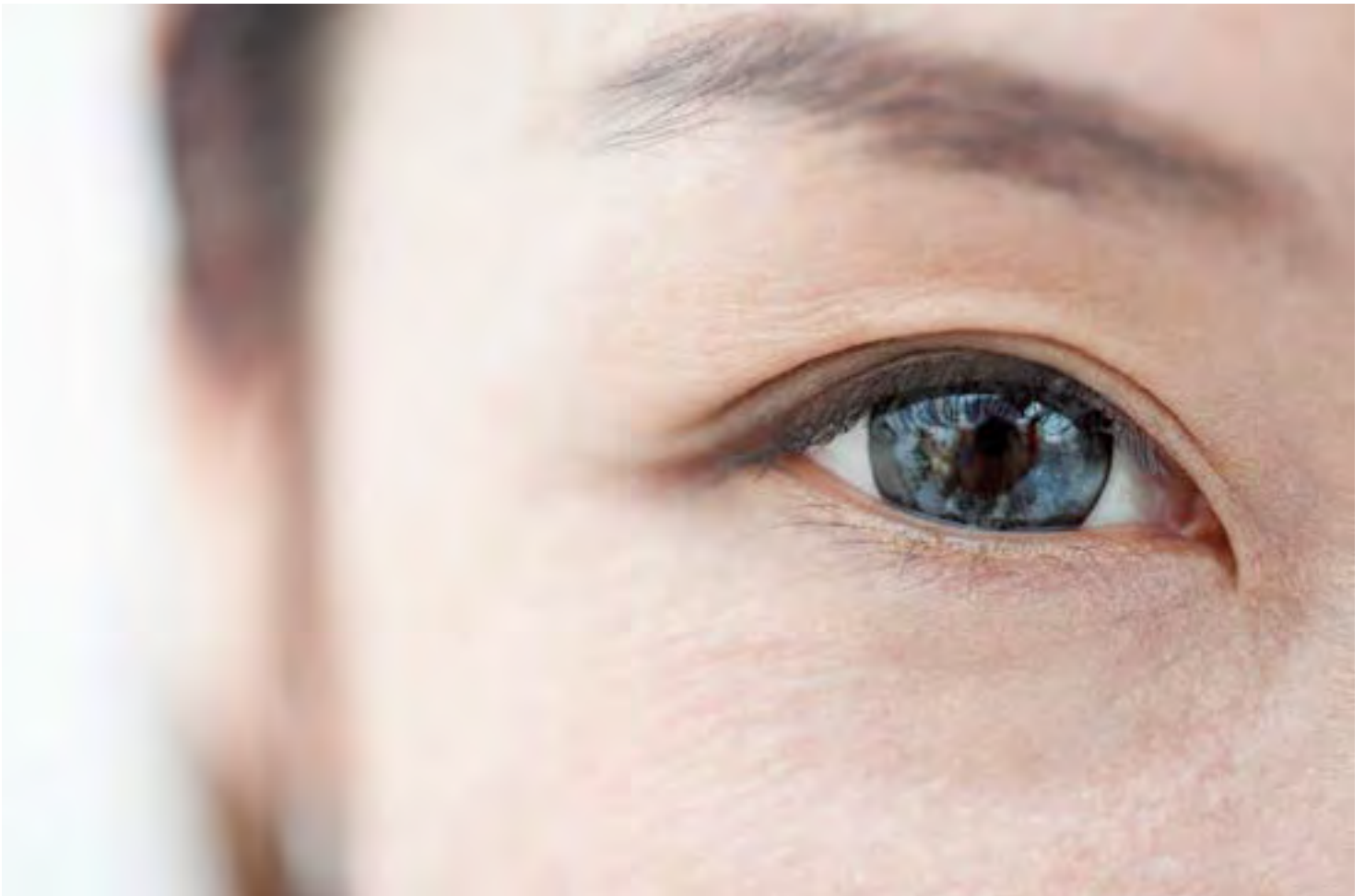## Outcome

We defended the claim in full and made no offers at any time. Ms R pursued her claim for three years, right up until the days before a full trial, when she discontinued her claim. Dr E was very grateful for the level of expertise and robust support from his Medical Protection legal team, who were determined to fight the case at a full trial if needed.

## Learning point

- From time to time unusual complications occur in medical treatment, but this does not necessarily mean there has been negligence. The onus is on a claimant to establish, on the balance of probabilities, that the clinician acted in a way no ordinarily competent clinician would have done if providing ordinary care.





# An expensive lack of consent?



By Dr Heidi **Mounsey**,  
Medicolegal Consultant, Medical Protection

**M**r N, a 44-year-old chemical engineer, consulted Dr B seeking laser eye surgery in order to correct short sightedness. At that time, Mr N's prescription was -6.00 in the left eye and -5.5 in the right. A mild degree of astigmatism was also noted. Mr N wore contact lenses and these provided adequate correction to his vision, with an acuity of 6/6 in both eyes.

However, Mr N reported to Dr B that he had been suffering with recurrent episodes of infection for the previous 16 months, making it difficult for him to wear the lenses. He was seeking an alternative to both contact lenses and spectacles.

Dr B took a medical history but did not appear to have elicited that a year previously, Mr N had been reviewed by a consultant ophthalmologist in his local hospital and been diagnosed with dry eyes. Mr N was prescribed lubricant drops at that time. This information was not documented in the history obtained by Dr B.

There was also no contemporaneous note made in relation to whether Mr N's tear film was normal, although in comments subsequently obtained from Dr B he stated that it was. It was not documented whether or not Mr N was using eye drops at the time of the consultation with Dr B, although a note was made of other medication.

Following discussion, Dr B considered that Mr N would be suitable for LASIK laser vision correction.

Mr N consented to bilateral LASIK surgery and this was performed without complication. The consent form was signed on the day of surgery and included the following risks:

- Corneal scarring or haziness
- Glare and halos
- Infection

- Ongoing need for glasses/contact lenses
- Problems with the corneal epithelium causing pain or discomfort
- Irregular healing of the cornea resulting in reduced quality of vision.

Dry eyes were not mentioned as a specific complication.

It was unclear from the medical records whether the patient had been provided with the consent form prior to the day of surgery. Mr N did, however, sign the consent form, including a statement to say that he understood that laser surgery would not prevent him from developing naturally occurring eye problems such as glaucoma, cataract, retinal degeneration or retinal detachment and that he understood if his myopia was corrected, then he would likely need reading glasses.



A week following the procedure Mr N's vision was 6/10 in both eyes. Three weeks after the procedure Dr B considered there was evidence of punctate epithelial erosions bilaterally. He diagnosed dry eyes and inserted punctal plugs, as well as prescribing lubrication drops.

Some six months after the surgery Mr N visited his optician and his prescription was found to be +1.00/-1.75 in the right eye and -1.00/-0.75 in the left eye. Once corrected, Mr N's visual acuity was 6/6.5 bilaterally.

Mr N expressed a desire for further correction and Dr B carried out LASEK treatment to the right eye. The consent form was signed on the day of treatment and contained similar risks to those listed for LASIK. Dry eyes were not specifically mentioned as a possible complication.

A month after the LASEK procedure Mr N complained that the vision in his right eye was very blurred. His refraction was noted to be +0.75/-2.75 with an acuity of 6/7. It was noted that his tear film was ok, but there is no record of whether or not Mr N was continuing to use lubricating drops.

Mr N continued to complain of difficulties with his vision with blurring and ghosting. It was also considered that the right eye had significant induced astigmatism following the LASEK procedure.

Ten months following the initial LASEK surgery, Dr B identified a posterior vitreous detachment in the left eye and Mr N underwent a left vitrectomy. Six months after this procedure his refraction was +1.00/-2.25 in the right eye and -1.25/-1.00 in the left eye. With correction, Mr N's visual acuity was 6/6 in the right eye and 6/12 in the left eye, although this was noted to be variable.

Mr N continued to be followed up by Dr B, and two years after the initial LASIK procedure Mr N was noted to have bilateral lens opacities, more in the left eye than the right. Dr B discussed bilateral lens replacement using multifocal lenses. It was not clear in the medical records whether the option of a single focus toric lens was discussed with Mr N. In any event, Mr N opted to have bilateral multifocal lens replacements.

Following the lens replacements, Mr N's visual acuity was 6/6 in the right eye, and 6/36 in the left, which improved to 6/20 using a pinhole. Dr B referred him to public health services for further review, at which point a left epiretinal membrane and an early full thickness macular hole were diagnosed. A left vitrectomy and membrane peel were performed without complications. Mr N remained under ophthalmology follow up in the public healthcare sector.

Three and a half years after the original LASIK procedure Mr N's corrected visual acuity was 6/10 in the right eye and 6/38 in the left eye, although these acuities were noted to be highly variable with blinking. Uncorrected, his acuities were noted to be 6/15 in the right eye and 6/60 in the left. Mr N continued to complain of double vision and ghosting and that his vision was particularly poor in low light. The Schirmer tear secretion test was reduced in both eyes. It was considered that Mr N's poor vision was due to a combination of poor pre-corneal tear film, especially in the left eye; induction of mild higher order aberrations associated with laser refractive surgery; reduced optics associated with multifocal intraocular lenses; and vitreous detachment and macular problems in the left eye.

### **The claim**

Mr N subsequently brought a clinical negligence claim against Dr B alleging that it was a breach of duty to have performed bilateral LASIK, right LASEK, and bilateral multifocal lens replacement surgery, and that he had not been adequately consented for any of these procedures. It was alleged that the surgeries resulted in very poor unaided vision bilaterally, including ghosting effects and double vision, and that the contact lenses he now needed to wear could only be tolerated for three hours a day, leaving him with significantly limited vision for the majority of the time. He alleged he was no longer able to work as a chemical engineer due to the limitations of his vision.

Mr N alleged that, had he been more fully informed of the risks of any of the procedures he underwent, especially the risk of dry eyes in association with LASIK and LASEK, he would not have opted for the surgeries.

It was further alleged that there would have been signs of cataract at the time of offering the initial LASIK procedure and this would have been a contraindication to performing the surgery.



*The consent form was signed on the day of treatment and contained similar risks to those listed for LASIK. Dry eyes were not specifically mentioned as a possible complication.*

In addition, it was stated that aberrometry should have been performed prior to recommending multifocal intraocular lens surgery and that this would have demonstrated Mr N to be unsuitable for this procedure.

It was also alleged that although Mr N had suffered with complications likely unrelated to Dr B's interventions, namely the posterior vitreous detachment, epiretinal membrane and macular hole, these had not impacted significantly on Mr N's vision in his left eye. Mr N's solicitors valued the claim, including loss of earnings, ongoing care needs and loss of pension, at a substantial amount.

### **Expert opinion**

The opinion of an expert consultant ophthalmic surgeon was sought following a detailed evaluation of the case by Medical Protection's clinical and legal teams.

The expert highlighted the following:

- A relevant history did not appear to have been taken by Dr B prior to advising and performing LASIK surgery. It was not noted whether Mr N had previously received any treatment in relation to his eyes or whether he was currently using any eye drops.
- It was not clear from the medical records and the consent form that Mr N was fully advised of all the options available to him, including that of no surgery.
- The consent form did not specifically include the risk of dry eyes following LASIK surgery.
- It is unlikely that there were signs of cataracts in Mr N's lenses at the time of the initial assessment by Dr B.

- There was no consent form for the LASEK surgery in Mr N's records, or evidence that the risks and benefits of this, and the other options available, were discussed with Mr N.
- Aberrometry should have been performed prior to recommending multifocal lens surgery. Had this been performed, it is likely Mr N would have been found to be unsuitable for this procedure. The use of multifocal lenses likely led to a worsening of Mr N's quality of vision.
- There were no consent forms in relation to the multifocal intraocular lens surgeries in Mr N's records, and no evidence that the risks and benefits of such surgery (and the alternatives) were discussed.
- Mr N's vitreous detachment, epiretinal membrane and macular hole were not as a result of any surgery performed by Dr B and had made a significant contribution to the poor vision in Mr N's left eye.
- There were now surface abnormalities to Mr N's right eye, which meant his vision could not be corrected with spectacles alone, and his dry eyes would make it more difficult for him to tolerate contact lenses.

Overall, the expert concluded that the consenting process for all procedures carried out by Dr B was inadequate, and that there was a failure to obtain a sufficient medical history and instigate appropriate tests to allow a fully informed discussion of the risks and benefits of the available options.

## Outcome

After a conference and full discussion with the expert and Dr B, it was agreed that admissions of breach of duty in relation to consent for all the procedures and failure to perform aberrometry prior to offering multifocal lens exchange should be made in the response to Mr N's solicitors.

Following this, a number of other experts were instructed by Mr N's solicitors and by Medical Protection on behalf of Dr B in order to consider the impact of Mr N's vision on his life, and the past and future financial losses incurred.

Expert opinions were sought in the areas of care and assistance, loss of earnings and pension loss, as well as ophthalmology and optometry.

Medical Protection was able to use the statements produced by these experts to argue that Mr N would always have suffered a left vitreous detachment, epiretinal membrane and macular hole. It was put to Mr N's solicitors that these non-negligent events did make a significant contribution to the reduction in the vision of Mr N's left eye.

It was further argued that there would not have been signs of cataracts at the time of the initial assessment, and therefore no contraindication for LASIK on that basis.

Medical Protection therefore considered that the claim was worth significantly less than alleged by Mr N's solicitors, given that much of the reduced vision in Mr N's left eye was not as a result of any procedure carried out by Dr B.

Following the admissions of breach of duty, but in light of the discrepancies in relation to causation and the value of the claim, it was agreed that Medical Protection and Mr N's solicitors would attend a meeting, in the presence of an independent mediator, in order to determine if the matter could be settled without the need for a trial.

The meeting led to settlement of the matter for over a third less than was originally claimed, and successfully avoided the need for Dr B to attend court, at which he would have been required to give evidence in relation to the treatment he provided and the consent process he had undertaken.

## Learning points

- **When taking a history, important negatives should be documented as this will help prevent any future allegations that the questions were not asked or that particular aspect of the patient's history was not explored.**
- **Ensure patients are provided with all the information they will need to make a considered decision, including the consent form, prior to the day of the surgery. A suitable cooling off period should also be given. In this case, although a month had elapsed between the consultation and the original LASIK surgery, it was unclear whether the patient had had the opportunity to fully discuss the risks and benefits of the available options and review the consent form in advance of the procedure.**
- **If using a pre-printed consent form, ensure the appropriate risks are included on this and, if not, ensure that it is clearly documented when the patient is advised of a risk not listed on the form.**
- **Ensure the necessary investigations are conducted and the results reviewed before deciding whether a procedure would be suitable for a particular patient.**



# Nitrofurantoin complication goes to trial



By Marshal **Ahluwalia**,  
Claims Manager, Medical Protection

**M**rs S was 64 years old and had a significant medical history that included rheumatoid arthritis, frequent urinary tract infections and giant cell arteritis. For a period of time she took methotrexate for her rheumatoid arthritis; the disease limited her mobility and she was morbidly obese, requiring the use of a wheelchair and care from her daughter and adult granddaughter, both of whom lived locally to her. Methotrexate had eventually been discontinued.

Mrs S was a frequent attender at her GP surgery for treatment of her medical conditions and was under the care of urologists for her frequent urinary tract infections. Mrs S had been taking 50mg of prophylactic nitrofurantoin each evening for a number of years, as prescribed.

Mrs S attended Dr B with a complaint of being a bit breathless when walking and swelling to her ankles. Dr B performed auscultation of the chest and bilateral crackles were noted but no rhonchi. Superficial phlebitis in the right lower leg was diagnosed. Dr B prescribed a short course of furosemide for 14 days and codeine for pain. She requested that Mrs S return for further examination at the end of the course.

A few days later Mrs S telephoned the surgery and spoke with Dr X, who was the GP on call that day. She informed Dr X that she was experiencing breathing problems and thought she could be suffering from cystic fibrosis. He noted she informed him that she had a cough, was breathless, felt cold and shivery and was tired. Dr X asked Mrs S to come to the surgery for a face to face consultation and she came in later that day.

On auscultation of the chest, Dr X found adequate air entry in all areas with unilateral crackles in the left lower zone. Mrs S had had a productive cough since the previous consultation with Dr B. She was breathless and felt shivery but was apyrexial.

Dr X diagnosed a chest infection and prescribed cefalaxin 500mg. Mrs S returned to see her GP on other occasions over the next couple of months but the notes did not suggest any symptoms of chest infection, until one consultation with Dr X where the presenting symptoms were the same as two months prior. Dr X considered this to be a new presentation of a chest infection and a further course of cefalaxin was prescribed.

A few days later, Mrs S contacted an out of hours service with a complaint of shivering with a raised temperature and shortness of breath. A diagnosis of chest infection was made. Her steroid prescription was increased to 30mg daily and she was prescribed clarithromycin.

Five days later, Mrs S reattended the surgery and was advised by Dr P to continue to take the prescribed antibiotics and continue with steroid inhalers. She was to be reviewed again the next day. Later that day, Mrs S underwent a chest x-ray.

The next day, Mrs S reattended with Dr P. The chest x-ray report was not available. The claimant was noted to “feel slightly better than last week, had CXR yesterday but no report available”. Her chest was examined and no wheeze or creps were found. Dr P requested that the claimant have her full blood count checked, a d-dimer and her U&Es checked.

Later that day Mrs S attended an out of hours clinic and was examined by another GP. She gave a history of having had a d-dimer test that afternoon, and she was tired, had a bad chest and her ankles were “always swollen”. She was noted to have had a “bad chest over last couple of weeks nil pleurisy – retrosternal pain nil haemoptysis”. Mrs S was subsequently examined by another doctor and upon examination gave a history of having three recent courses of antibiotics for a chest infection, but that she was noted to be “well perfused and hydrated SOB no cyanosis no recession good bilateral air entry – no dullness no chest pain”. A diagnosis of dyspnoea was made and the plan, in view of Mrs S’s worsening symptoms of shortness of breath and tachycardia, was of investigation for a pulmonary embolism and possible chest infection. She was subsequently admitted to hospital.

Following discharge from her local hospital, Mrs S attended the Emergency Department at a different hospital later that day. The working diagnosis was a lower respiratory tract infection with abnormal liver function test results and Mrs S was to have an ultrasound scan of her abdomen, her LFTs were to be repeated and the nitrofurantoin was continued.

Three days later, the diagnosis of pulmonary fibrosis secondary to rheumatoid arthritis and methotrexate therapy was considered; Mrs S was sent for respiratory referral. Nitrofurantoin was continued.

A CT scan was undertaken two days later. The scan was reported as showing widespread fibrosis in the chest. The appearance was consistent with acute nitrofurantoin lung. Nitrofurantoin was stopped by the respiratory team as it was felt to be the causative agent for the fibrosis.

Mrs S was discharged from hospital a week later but remained under the care of the respiratory team.

Three months later, concern was raised about the aetiology of the fibrosis. Radiology was reviewed at an MDT meeting and it was agreed that the clinical and radiological picture would fit with sub-acute nitrofurantoin pulmonary toxicity.

After the nitrofurantoin was stopped, the claimant’s condition improved and she was discharged home on trimethoprim with care from family members.



*The appearance was consistent with acute nitrofurantoin lung. Nitrofurantoin was stopped by the respiratory team as it was felt to be the causative agent for the fibrosis*

### The claim

Mrs S instructed solicitors to bring a negligence claim, alleging that her nitrofurantoin should have been stopped by the GPs when she originally presented and, had that occurred, she would not have experienced breathlessness necessitating hospital admission. She claimed that she developed dysfunctional breathing and hyperventilation syndrome as a result of the alleged negligence of the two GPs, Dr X and Dr B, which had adversely affected her mobility, weight, quality of life and ability to work.

Mrs S claimed that her GPs should have been aware of the link between nitrofurantoin and pulmonary fibrosis and their failure to consider this link when assessing her was a breach of their duty of care. She claimed that based upon her presenting symptoms she should have been referred for an urgent chest x-ray. Upon receipt of that chest x-ray, Mrs S claimed, it would have shown worrying signs and the reasonable GP would have stopped the nitrofurantoin prescription immediately. She claimed this would have avoided the impact on her weight, quality of life, mobility and income.



## How Medical Protection helped

Dr X was a member of Medical Protection and we assembled a legal team to assist him, along with an external solicitor firm. Proceedings were also brought against Dr B, who was separately represented.

Evidence from a GP expert was supportive of Dr X's initial care of Mrs S but questioned his care later on. The expert suggested that more effort should have been made to find out the results of the CXR, which would have shown evidence of fibrosis.

Evidence was also obtained from a consultant respiratory physician to comment upon Mrs S's likely treatment and impact of that treatment had it been provided earlier, and from a radiologist on what an urgent CXR, had it been performed, would have shown. Additional expert evidence was obtained from a rheumatologist.

The claim was strongly defended on behalf of Dr X. It was also defended by Dr B.

The experts for the defendants and Mrs S met to discuss the case and the radiologists agreed it was impossible to say what an urgent x-ray after the first consultation would have shown. They agreed that any x-ray taken following the later consultation would have shown similar but less worrying signs than those revealed in the CT scan conducted in hospital.

The GP experts agreed that the reasonable GP may not be aware of the link between nitrofurantoin and pulmonary fibrosis. However, they disagreed on Mrs S's likely presenting symptoms during her initial GP consultations, and on what signs and symptoms would be present if she had presented with a chest infection or a reaction to nitrofurantoin adversely affecting the lungs.

Despite pulmonary fibrosis being diagnosed by her treating clinicians, the parties' experts agreed that on the balance of probabilities, Mrs S did suffer from nitrofurantoin induced lung toxicity but did not have pulmonary fibrosis; she had suffered from pneumonitis, which had resolved after discontinuance of the nitrofurantoin. Any residual breathing problems after resolution of the pneumonitis was due to the pre-existing rheumatoid arthritis.

The claim proceeded to trial.

## The outcome

The day before the trial commenced, Mrs S sought to amend her pleaded claim against Dr B, claiming that Dr B should have investigated Mrs S for heart failure based upon her initial presentation. While this had been alluded to in Mrs S's evidence from her GP expert, she had chosen not to make the point until the day before the trial.

Due to the way the proposed amendment to the pleading was drafted, it would also have had an impact on the case against our member, Dr X. The proposed amendment was opposed as it was considered prejudicial to the defendants – as they had not been able to provide witness or expert evidence in response to the new allegations, and it was coming extremely late and could impact upon the trial.

On the second day of trial, Mrs S asked the trial judge to give specific reasons why their application to amend her pleaded case was not granted. The trial judge gave his reasons, and he was particularly critical of Mrs S's legal team and the way they had conducted the case.

Mrs S then sought permission to appeal the decision to refuse the proposed amendment. Permission for appeal was refused by the trial judge. The trial was then adjourned for a short period and, during that time, instructions were obtained by Mrs S's legal team from the insurers funding her claim. It became clear that her funding for the claim had been withdrawn.

**“ ”**

*The GP experts agreed that the reasonable GP may not be aware of the link between nitrofurantoin and pulmonary fibrosis. However, they disagreed on Mrs S's likely presenting symptoms during her initial GP consultations*

The claimant discontinued her claim against both defendants on the afternoon of the second day of trial.


On behalf of Dr X, an order for indemnity costs was sought and successfully obtained in respect of a proportion of the costs incurred on his behalf. In essence, indemnity costs were ordered in this case to penalise Mrs S for the poor way her claim had been handled and conducted.

**“ ”**

*The trial judge gave his reasons, and he was particularly critical of Mrs S's legal team and the way they had conducted the case.*

### Learning points

- While GPs should be aware of the potential link between nitrofurantoin and breathing problems, there is a reasonable body of GPs who would not have known of that link back when this case occurred. Any such diagnosis is unlikely to be made by a GP and is most likely to be made by respiratory physicians in a hospital setting.
- The British National Formulary offers the following guidance that is applicable to patients on long-term nitrofurantoin: “In adults: on long-term therapy, monitor liver function and monitor for pulmonary symptoms, especially in the elderly (discontinue if deterioration in lung function).”



# A tale of greed and dishonesty



By Dr Dawn **McGuire**, *Medicolegal Consultant*, and Marshal **Ahluwalia**, *Claims Manager, Medical Protection*

**M**r F was a 30-year-old painter. During the 2010 swine flu epidemic, he received a course of Tamiflu after developing fever and flu-like symptoms. His symptoms deteriorated whereby he became short of breath and was bringing up dark sputum. He consulted Dr A who diagnosed H1N1 flu and advised conservative treatments. Three days later, Mr F was admitted for suspected pneumonia when his heart rate was 120 with an oxygen saturation of 85%.

Mr F was subsequently diagnosed with severe pneumococcal pneumonia, complicated by multilocular empyema and acute renal failure. He required a thoracotomy for complete decortication of his empyema.

## The claim

Mr F brought a clinical negligence claim against Dr A for failure to admit to hospital. Mr F insisted Dr A did not examine him at all. Dr A could not recall the details of the consultation as he saw many patients with similar presentations during the swine flu epidemic. There was no recorded evidence that Dr A undertook an examination of Mr F's heart rate, respiratory rate and oxygen saturation. Medical Protection therefore agreed to settle on behalf of Dr A as the brevity of consultation record was inadequate to assist in defending this claim.

Mr F, however, rejected the proposed settlement offer as he was hoping for a substantially higher offer. Mr F alleged

that he had developed complex post-thoracotomy chronic pain syndrome making him almost housebound with disability, cold intolerant, deeply depressed, unemployable and a social recluse. Mr F initially demanded £50,000 but this then escalated to £300,000 and a final demand for £1.5 million.

The Medical Protection legal team carried out due diligence and initiated a social media investigation into Mr F's life, which exposed his normal active lifestyle of playing cricket and tennis even in the coldest months of the year, frequent family outings and regular social events.

Our team submitted that Mr F had fraudulently exaggerated the extent of his injuries and intentionally provided inaccurate and misleading evidence to the experts. Subsequent enquiries with the relevant government departments also exposed Mr F's similarly misleading account of his fabricated disability, which earned him an enhanced rate benefit to assist with his daily living and mobility needs. Mr F debated that he had a sudden remarkable improvement but had not disclosed this to all relevant parties in time; he reduced his claim demand by 66%.

Medical Protection rejected this and contended that we were no longer able to assume that Mr F's account of the 2010 consultation (in particular, that he recalled no examination was undertaken) honestly reflected his genuine recollection. Mr F then confirmed his intention to discontinue his

claim but refused to accept our terms of discontinuance. At trial, the judge permitted the claim to be discontinued and awarded a costs order in Dr A's favour. Medical Protection had incurred defence costs of £200,000 to instruct panel solicitors, counsel and experts to assist Dr A and managed to recover half of this from Mr F's insurers.

The Medical Protection legal team also considered contempt proceedings against Mr F and the possibility of taking steps to recover the outstanding legal costs incurred in defending the claim, but Mr F subsequently sold his house, which he jointly owned with his wife, and filed for bankruptcy. Nonetheless, the outcome of the claim was an excellent one for Dr A as he had been completely exonerated from any culpability.

## Learning points

- **The process of handling a claim can be a long one, with numerous developments along the way. In this case, Dr A's legal team became suspicious of Mr F's demands and, when it became clear he was behaving fraudulently, we were persistent in taking the right steps towards achieving a good outcome for Dr A.**
- **Although successful on this occasion, the poor record keeping demonstrated could have resulted in a far worse result.**

# Scaphoid injuries: pitfalls and pearls



The failure to diagnose scaphoid injuries is a common source of claims at Medical Protection. Dr Emma Green, Medicolegal Consultant at Medical Protection and Emergency Medicine Doctor, advises on the common pitfalls and how to avoid them



**M**issed fractures can result in multiple adverse outcomes for patients. Often, causation issues in claims flow from delays in diagnosis, as earlier diagnosis allows for immobilisation or operative management in some fractures.

FOOSH (fall on outstretched hand) is the most common mechanism of scaphoid fracture although other mechanisms can include blunt scaphoid trauma as well as repeat stress type injury. These injuries can also be associated with radial fractures, especially in older populations, but unless a scaphoid injury is considered it is unlikely to be diagnosed.

### Pitfall 1: Incorrectly interpreting the mechanism

**Injuries in sport, such as a goalkeeper saving a ball or any hyperextension injury with loading, can sometimes be misinterpreted in terms of mechanism, increasing the risk of missing a scaphoid fracture. Consider these in the same way as a direct FOOSH.**

**Examination should include the wrist, as radial fractures are also common with the same mechanism of injury. Additional tests should, however, be undertaken in relation to the scaphoid and documented clearly.**

### Special tests for scaphoid injury

- Tenderness over anatomical snuff box
- Tenderness over scaphoid tubercle
- Telescoping (hold thumb firmly and apply pressure towards the metacarpal bones)
- Tenderness over scaphoid tubercle.

### Clinical signs are not necessarily diagnostic

The above tests are reported to have high sensitivity but specificity of 9%, 30% and 48% respectively.<sup>1</sup>

However, in reality, these signs are not always present despite competent examination even in early presentation. In a study by Waizegger et al<sup>2</sup> 12 clinical signs associated with scaphoid fracture were examined within three days of injury and again at two weeks. The study found a history of an extension injury, tenderness in the snuff box and pain elicited in the snuff box, with resisted supination, to be the most reliable clinical indicators of a recent scaphoid fracture. However, none of these findings were invariably present.

Many patients without a scaphoid fracture have identical signs and symptoms, so no test is completely reliable. This may assist in defending cases where clinical examination has been documented but does not necessarily provide a robust defence. Expert orthopaedic surgeons have commented that signs may also reduce after a time period due to healing with scar tissue.

Clinical records should contain sufficient information to show that the relevant history and examination were undertaken. The clinical examination should be sufficient to raise clinical suspicion of scaphoid injury.

### Primary care

Patients are usually seen in the Emergency Department following injury, where they may be given a diagnosis of wrist sprain. Re-examination in primary care if a patient presents and has not had an x-ray may offer an opportunity to make a diagnosis. This can also be a chance to consider whether the appropriate imaging was done.

### Pitfall 2: Wrist x-ray or scaphoid series?

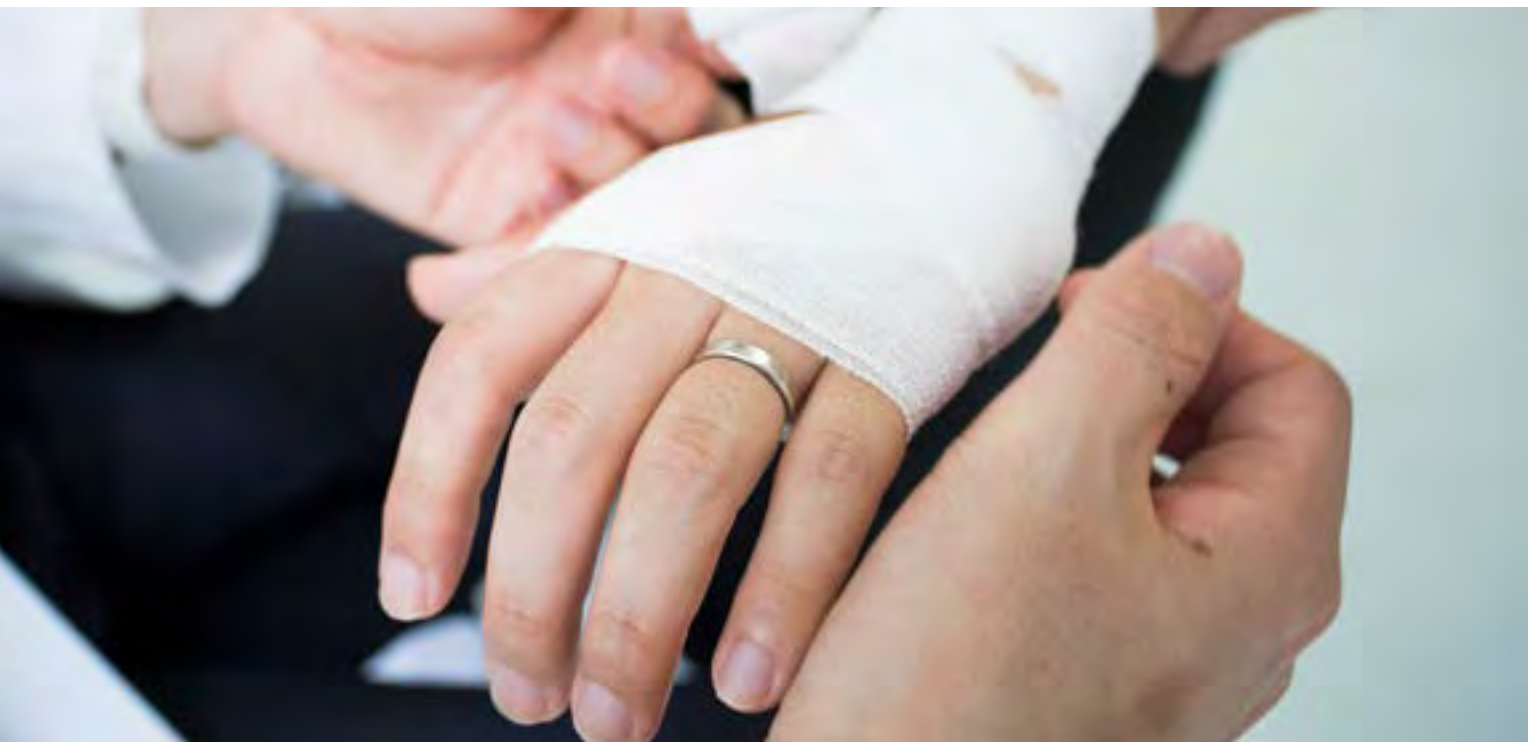**A wrist x-ray is insufficient in suspected scaphoid injuries. Based on retrospective studies and cadaveric review, the most sensitive radiographic evaluation includes four views: PA, lateral, pronated oblique (60° pronated oblique) and ulnar deviated oblique (also described as 60° supinated oblique).<sup>3</sup>**

### Pitfall 3: Lag in radiologically visible fracture

**Scaphoid fractures may take 7-14 days to be radiologically visible. Patients who have only had one x-ray for suspected scaphoid fracture should be considered to have a fracture until two negative x-rays or they have had a negative MRI scan, depending on local policy.**

### Risks of missing a fracture

Avascular necrosis is a recognised complication associated with waist and proximal pole fractures. Non-union of scaphoid fractures can result in a need for bone grafting, which can impact the value of a claim and create the potential for ongoing symptoms from synovium inflammation



and scarring. Scaphoid non-union advanced collapse is also associated with chronic non-union where a non-union period of more than five years has a less favourable outcome.

### Scaphoid claims: the medicolegal view

When considering the value of a scaphoid claim, case law examples below show that the value can vary depending on long-term disability and outcome, but can be considered between £10,000 and £40,000 as a broad ballpark figure.

*M v Royal United Hospital Bath NHS Trust (2010)* where the claimant, a 31-year-old man, received £10,000 PSLA (pain, suffering and loss of amenity) for the alleged failure to correctly diagnose and treat his scaphoid fracture for four months. He later had to undergo percutaneous screw fixation and bone grafting surgery.

*JK v Lancashire Teaching Hospitals NHS Foundation Trust (2013)* where the claimant, a 37-year-old man, received £25,000 PSLA for a medical failure to diagnose his wrist fracture in October 2005. The claimant suffered pain and stiffness in his wrist for four years until the fracture was diagnosed; he underwent surgical procedures and was only expected to make a 90% recovery in the future.

### Medical Protection case study

Dr D, a GP, saw Mr C, a 35-year-old left-handed unemployed man who sustained an injury while playing football. He was saving a shot and his right wrist had been forced into hyperextension by the ball. He had immediate pain over the wrist and attended his GP within 24 hours. He also reported some pain in the left wrist, but less so than the right.

Dr D took a full history and examined the wrist. There was noted to be tenderness over the radial styloid. There was no documented examination of the anatomical snuff box or evidence to suggest scaphoid examination had occurred.

Dr D felt that this was most likely a wrist sprain and prescribed analgesia. No x-ray was requested. Although Dr D felt he would likely have given worsening advice or safety netting at this point, this was not recorded in the clinical record.

Twelve months later Mr C registered with a new GP and reported that he still had ongoing pain in his wrist. An examination raised suspicion of scaphoid injury and an x-ray was ordered. This showed a scaphoid non-union fracture. Mr C required an operation with bone grafting and reported ongoing grip weakness. He made a claim against Dr D.

Dr D advised Medical Protection that the scaphoid had not been examined and this was why it was not recorded in the medical record, as he did not consider this to be a typical mechanism for scaphoid injury.

The claim was settled for a low value after expert evidence conceded that the delay in diagnosis had contributed to the non-union fracture and a subsequent need for arthroscopy. The expert also felt that appropriate examination would have likely revealed some clinical signs to raise suspicion of fracture, given that signs were found one year later. The settlement value reflected the fact that Mr C had not reattended his GP to report ongoing pain and the fact his records showed that the injury had not impacted on his employment prospects.

This case highlights the need to consider that hyperextension with loading through this mechanism should be considered in the same way as a FOOSH.

### Conclusion

Scaphoid claims are a recurring theme in the context of a missed diagnosis at primary care review, or where primary care have seen a patient after they have been seen in secondary care and not had scaphoid imaging.

This can raise the question of where breach of duty ultimately lies but it reinforces the importance of consideration of scaphoid fracture in the context of suspected wrist injuries.

### References

1. Freeland P, Scaphoid tubercle tenderness: a better indicator of scaphoid fractures? *Arch Emerg Med* 6(1):46–50 (1989)
2. Waizegger et al, Clinical Signs in Scaphoid fracture, *Journal of Hand Surgery* 19B: 6: 743-747 (1994)
3. <https://emedicine.medscape.com/article/328658-overview>



# Over to you

## A troublesome lump

The soft tissue sarcoma guidance from NICE CG27 given on page 10 of Casebook November 2019 felt unfamiliar. Perhaps it was the relevant guidance at the time of the case, but on the NICE website it was replaced in 2015 by NG12 (updated in 2017) and perhaps this should have been made clear. This is markedly different, suggesting ultrasound within two weeks for “unexplained” lumps that are increasing in size (within 48 hours for children and young people).

In contrast with CG27 it makes no reference to features such as depth, mobility or pain, nor to direct referral without imaging. I wonder how “unexplained” should be interpreted, and whether a clinical diagnosis of a benign cause is sufficient justification to forego imaging, avoiding flooding imaging facilities with requests for urgent scans on what will be overwhelmingly benign lumps? Presumably it will be only the vagaries of expert opinion and a judge’s ‘preferred’ evidence that decide this point, the next time a rare diagnosis causes an adverse outcome. In the meantime, how does the prudent generalist weigh the guidance against both clinical judgement and the GMC requirement to use resources effectively? This uncertainty tends to dispel the reassurance that might otherwise be derived from the successful defence of Dr C.

Dr J Moore, GP

*I note that the NICE guidance we referred to in the case study was the guidance in use at the time of the incident (CG27), and as you point out this has since been updated to NG12. I agree it would have been helpful to make it clear that the guidance has changed since the time of the case, and we have amended our online version of this case report accordingly.*

## Congratulations on Casebook

To again congratulate you on yet another excellent edition of Casebook. Thank you. Over the years Casebook has been the most important journal I read, but even more so now that I am just doing medicolegal reports in the area of orthopaedics.

**Please keep up the good work.**

Desmond Mackey

## A missed diagnosis of pneumonia?

I am moved to write to you about the way you represented this case. Yes, it is no doubt true that good record keeping is important and Dr N was conscientious, but Mrs P is also right to feel that the advice she received was of a poor standard – and this case displays some classic poor clinical reasoning that a senior medical student should recognise.

I have some credibility here as a paediatric infectious disease specialist and international expert on pneumococcal disease. I simply don’t believe that, given Mrs P required intubation and ventilation “shortly” after arriving at hospital and sounds as if she had sepsis with S pneumoniae in blood cultures, that there wasn’t more to see on the part of both Dr N and Dr R. Given subsequent events, I am much more inclined to believe Mrs P’s account of her status at consultation.

Even at original ED presentation muscle spasm was a flabby diagnosis but three days later with a history of “hurt when she breathed” it is breathtakingly flabby. I’m afraid Dr N manifestly erred in not taking temperature and even if not elevated, obtaining a CXR to rule out pneumonia was indicated. In a previously healthy adult, just as in an older child, because serious sepsis is rare and I do acknowledge it is rare in GP, awareness is often low – reduced oxygen saturation is only present in very severe bacterial pneumonia and its absence is by no means a ‘rule out’. Similarly, apparent chest tenderness in an unwell patient – I reiterate I believe Mrs P – is not too surprising in the presence of pleuritic pain from pneumonia, which at that time was surely present.

This is a classic example of poor decision making and one that medical students and trainees in general practice could learn from – good records of poor decisions do not good decisions make. Dr N (and Mrs P) are very lucky she did not die and I suspect views about the circumstances would have been very different if this had happened. It would be nice if Medical Protection did not simply point to avoidance of legal sanction as the goal but rather good medical practice – which this was not.

Peter McIntyre PhD, FRACP

*I note your concerns about this case report, published in the May 2019 edition of Casebook.*

*Firstly, I must point out that a challenge we face in publishing any case report is that it requires the summarising of a very lengthy and complex case down to a limited word count. It is inevitable that some detail and nuance is lost, but we hope to still be able to encourage learning from each case.*

*As background to the case, where a case is brought against one of our members we investigate it carefully, with the help of expert opinion, in order to determine if it can be defended or if there has been negligence requiring compensation of the patient. In this case we obtained supportive expert opinion from both a GP and a respiratory physician and so the case was defended on this basis.*

*We publish case reports so that members can learn from the experiences of others, which in turn we hope promotes learning and good medical practice. We include the comments of the expert opinions we obtain in managing the case to help to inform readers about the expert views of the care provided. We also indicate whether the case was settled or successfully defended, not as a goal as such, but to inform members of the outcome.*

*Members do sometimes disagree with the views of the experts in the case reports, but I hope this does not detract from the overall learning that can be taken from their publication.*



# Here to protect your wellbeing

At Medical Protection, we're not only here to protect your career and reputation, but your wellbeing too. Our job is to protect you in both the good times and the bad.

Our counselling service is available for all members who are experiencing work-related stress, or stress that they feel could impact their practice.

The service is entirely independent and confidential and is provided by our trusted partners ICAS.

The counselling service provides immediate access to support 24 hours a day, 7 days a week.

Find out more about how we can help you at  
[medicalprotection.org/counselling](https://www.medicalprotection.org/counselling)

# Contacts

## You can contact Medical Protection for assistance

### Medicolegal advice

#### Hong Kong

Freecall **800 908 433**

[querydoc@medicalprotection.org](mailto:querydoc@medicalprotection.org)

#### Malaysia

Freecall **1800 815 837**

[querydoc@medicalprotection.org](mailto:querydoc@medicalprotection.org)

#### Singapore

Freecall **800 616 7055**

[querydoc@medicalprotection.org](mailto:querydoc@medicalprotection.org)

### Medicolegal enquiries

#### Hong Kong

Freecall **800 908 433**

[mps@hkma.org](mailto:mps@hkma.org)

#### Malaysia

Freecall **1800 815 837**

[mps@mma.org.my](mailto:mps@mma.org.my)

#### Singapore

Freecall **800 616 7055**

[mps@sma.org.sg](mailto:mps@sma.org.sg)

Calls to Membership Services may be recorded for monitoring and training purposes.

### Medical Protection

Victoria House  
2 Victoria Place  
Leeds LS11 5AE  
United Kingdom

[info@medicalprotection.org](mailto:info@medicalprotection.org)

In the interests of confidentiality please do not include information in any email that would allow a patient to be identified.

# medicalprotection.org

---

---

---

---

The Medical Protection Society Limited ("MPS") is a company limited by guarantee registered in England with company number 00036142 at Level 19, The Shard, 32 London Bridge Street, London, SE1 9SG. MPS is not an insurance company. All the benefits of membership of MPS are discretionary as set out in the Memorandum and Articles of Association. MPS® and Medical Protection® are registered trademarks.